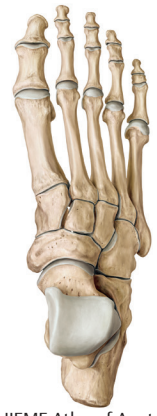

CHAPTER

1

Introduction and an Overview of the Bones of the Lower Limb



© THIEME Atlas of Anatomy

Introduction

The lower limbs are caudal appendages from the trunk, specialized for the transmission of the body weight and locomotion. The lower limb extends from the hip to the toes. It comprises four major parts or regions: gluteal, thigh, leg, and foot (**Fig. 1.1**).

The common people's reference to the lower limb as the leg, in fact, refers only to the part of the lower limb between the knee and the foot.

Gluteal region: The gluteal region overlies the side and back of the pelvis. The gluteal region comprises a rounded, prominent region, the buttock, and a less prominent region, the hip. It extends from the waist down to the gluteal fold, which limits the buttocks inferiorly, and to the hollow on the lateral side of the hip. Usually, the hip and buttocks are not clearly distinguished from each other. The hip is the lateral aspect of the region, while the buttock is a rounded bulge behind. The groove between the buttocks is called the *natal cleft*. The lower part of the sacrum and coccyx can be felt in this groove. Anterior to the gluteal region lies the perineum, in the depth of the cleft, and it continues forward between the thighs.

This region contains the hip bone. It comprises three parts, the ilium, ischium, and pubis, which are fused at the acetabulum where the head of the femur articulates with it. The *ilium* is the expanded upper part with a crest, the *iliac crest*, which can be felt in the lower margin of the waist at the level between the L3 and L4 vertebrae. The ischium is the posteroinferior part. It consists of the ischial tuberosity and ramus on which the body rests during the sitting position. The *pubis* is the anterior part and comprises a body and the superior and inferior pubic rami. The body of the pubis articulates with its fellow of the opposite side through a median fibrocartilaginous pad, the *pubic symphysis*. It may be felt at the lower end of the abdominal wall in the median plane. Draw your finger laterally from the symphysis on the anterosuperior surface of the body of the pubis. The bone felt is the *pubic crest*, which ends in a small, blunt prominence, the *pubic tubercle*, 2.5 cm laterally. In males, it is not easily palpable as it is covered by the spermatic cord.

Thigh region: The thigh region lies between the gluteal, abdominal, and perineal regions proximally and the knee region distally. It contains the femur, which connects the hip and the knee. The femur articulates at the upper end with the hip bone to form the hip joint and at the lower end with the tibia and patella to form the knee joint.

The junction between the trunk and the lower limb is abrupt anteromedially. The boundary between the abdomen and the lower limb, the inguinal ligament, extends between the anterior superior iliac spine and pubic tubercle. This junction between the two regions is called the inguinal region or groin.

Leg (*L. crus*) or leg region: The leg region extends from the knee joint to the ankle joint. The leg contains two bones, the tibia and fibula, which are united along the length by the interosseous membrane. The soft fleshy prominence on the back of the leg is called the *calf* and is formed by the triceps surae muscle. The lower end of the tibia and fibula form prominences on the medial and lateral sides of the ankle to form the *medial and lateral malleoli*. The flattened upper surface of the expanded proximal end of the tibia articulates with the lower end of the femur at the knee joint. The proximal end of the fibula articulates with the inferolateral surfaces of the lateral condyle of the tibia and does not take part in the formation of the knee joint.

Foot (*L. Pes*) or foot region: The foot region is the distal part of the lower limb and extends from the heel to the tips of the toes. It contains the tarsus, metatarsals, and phalanges. Its superior surface is the *dorsum of the foot*, while its inferior surface is the *sole of the foot*, which comes in contact with the ground.

An Overview of the Bones of the Lower Limb

A brief account of the bones of the lower limb is necessary before beginning to dissect so that the student studies the surface anatomy and relates it to the appropriate dried bone. The bones of the lower limb include the hip bone, femur, patella, tibia, fibula, and foot bones (**Fig. 1.2**).

Hip bone (Fig. 1.3): The hip bone is a large, flat bone formed by the fusion of three primary bones, the ilium, ischium, and pubis. At birth, the components are joined with each other by a Y-shaped triradiate hyaline cartilage (**Fig. 1.3**). By adulthood, they are ossified.

The hip bone looks like a propeller with a large sinuous blade directed upward and a smaller blade directed downward. The upper blade is called the ilium, and the lower blade consists of the ischium and pubis. It is perforated by a large aperture, the *obturator foramen*. The lateral aspect of the hip bone at the junction of the two blades presents a cup-shaped hollow called the *acetabulum*. Posteriorly, each hip bone articulates with the sacrum at the sacroiliac joint.

Ilium: The ilium's flattened upper border is called the iliac crest. It runs backward from the anterior superior iliac spine to the posterior superior iliac spine. It can be felt at the lower margin of the waist and below each of these spines are the corresponding inferior spines. The outer surface of the ilium is termed the "gluteal surface," which provides attachment to the gluteal muscles. The inferior, anterior, and posterior *gluteal* lines demarcate bony attachments of these muscles. The inner surface of the ilium is smooth and hollowed out to form the *iliac fossa*. It provides attachment to the iliacus muscle. The articular surface of the ilium articulates with the sacrum at the sacroiliac joints. The iliopectineal line runs anteriorly on the inner surface of the ilium, from the auricular surface to the pubis.

Ischium: The ischium forms the posteroinferior part of the hip bone. It comprises a spine on its posterior part, which demarcates the greater sciatic notch (above) from the lesser sciatic notch (below). The ischial tuberosity is a thickening on the lower part of the body of the ischium, which bears the body's weight in the sitting position. The *ischial ramus* projects forward from the tuberosity to meet with the *inferior pubic ramus* to form the *ischiopubic ramus*.

Pubis: The pubis forms the anteromedial part of the hip bone. It comprises a body and superior and inferior pubic rami. It articulates with the pubic bone of the contralateral side by a secondary cartilaginous joint (the symphysis pubis). The superior surface of the body bears the pubic crest and the pubic tubercle. The large obturator foramen is bounded by the pubis, ischium, and their rami.

Femur (Fig. 1.4): The femur is the longest and heaviest bone in the body. It transmits the body weight from the hip bone to the tibia. It presents the following characteristic features:

1. **Femoral head:** It articulates with the acetabulum of the hip bone at the hip joint. It extends from the femoral neck and is rounded and smooth. It forms two-thirds of the sphere and is covered with articular cartilage except for a medially placed depression or pit called the fovea to which the ligamentum teres is attached. This configuration permits a wide range of movement. The head faces medially, upward, and forward into the acetabulum.
2. **Femoral neck:** It forms an angle of 125 degrees with the femoral shaft, the *neck shaft angle*. This angle is less in females because of the increased width of the pelvis.

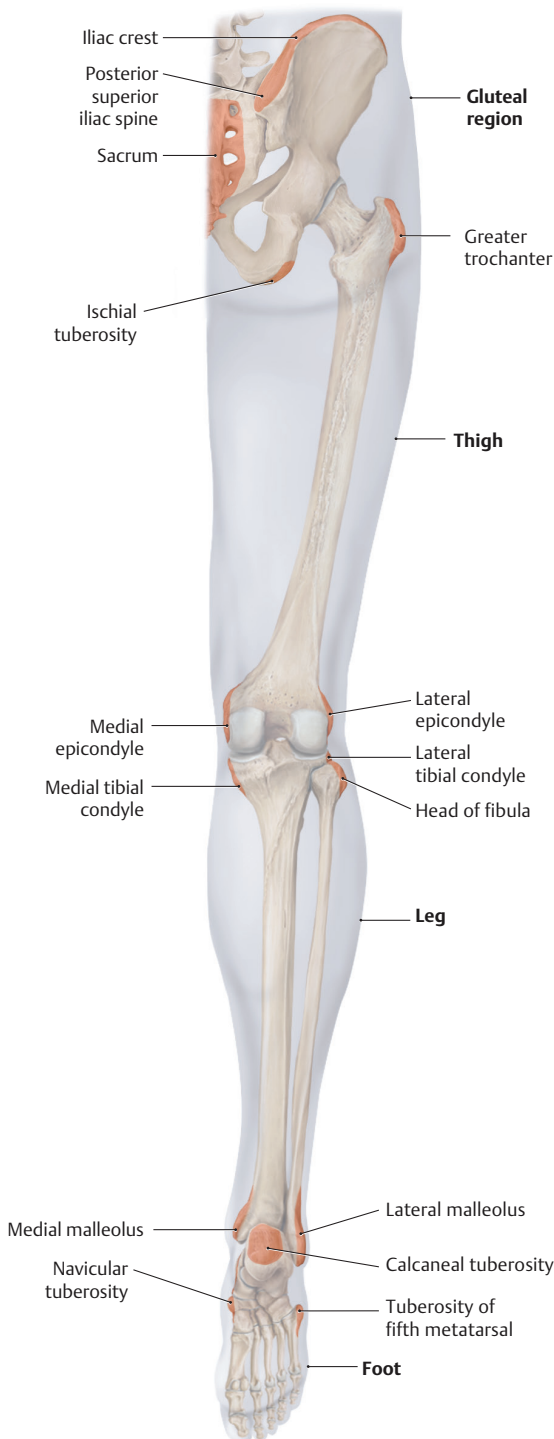


Fig. 1.1 Regions of the lower limb. (Reproduced with permission from Schuenke M, Schulte E, Schumacher U. Thieme Atlas of Anatomy. General Anatomy and Musculoskeletal System. Illustrations by Voll M. and Wesker K. © Thieme 2020.)

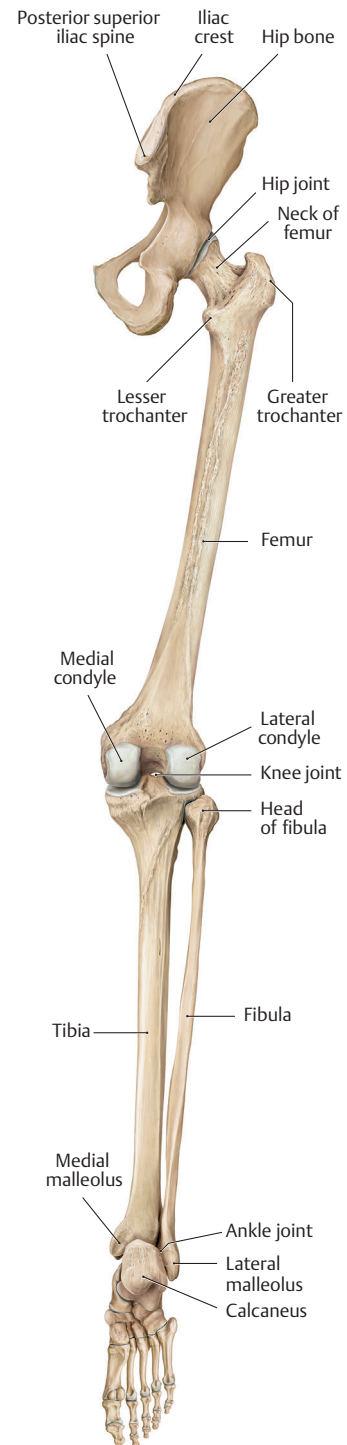


Fig. 1.2 Bones of the lower limb (posterior view). (Reproduced with permission from Schuenke M, Schulte E, Schumacher U. Thieme Atlas of Anatomy. General Anatomy and Musculoskeletal System. Illustrations by Voll M. and Wesker K. © Thieme 2020.)

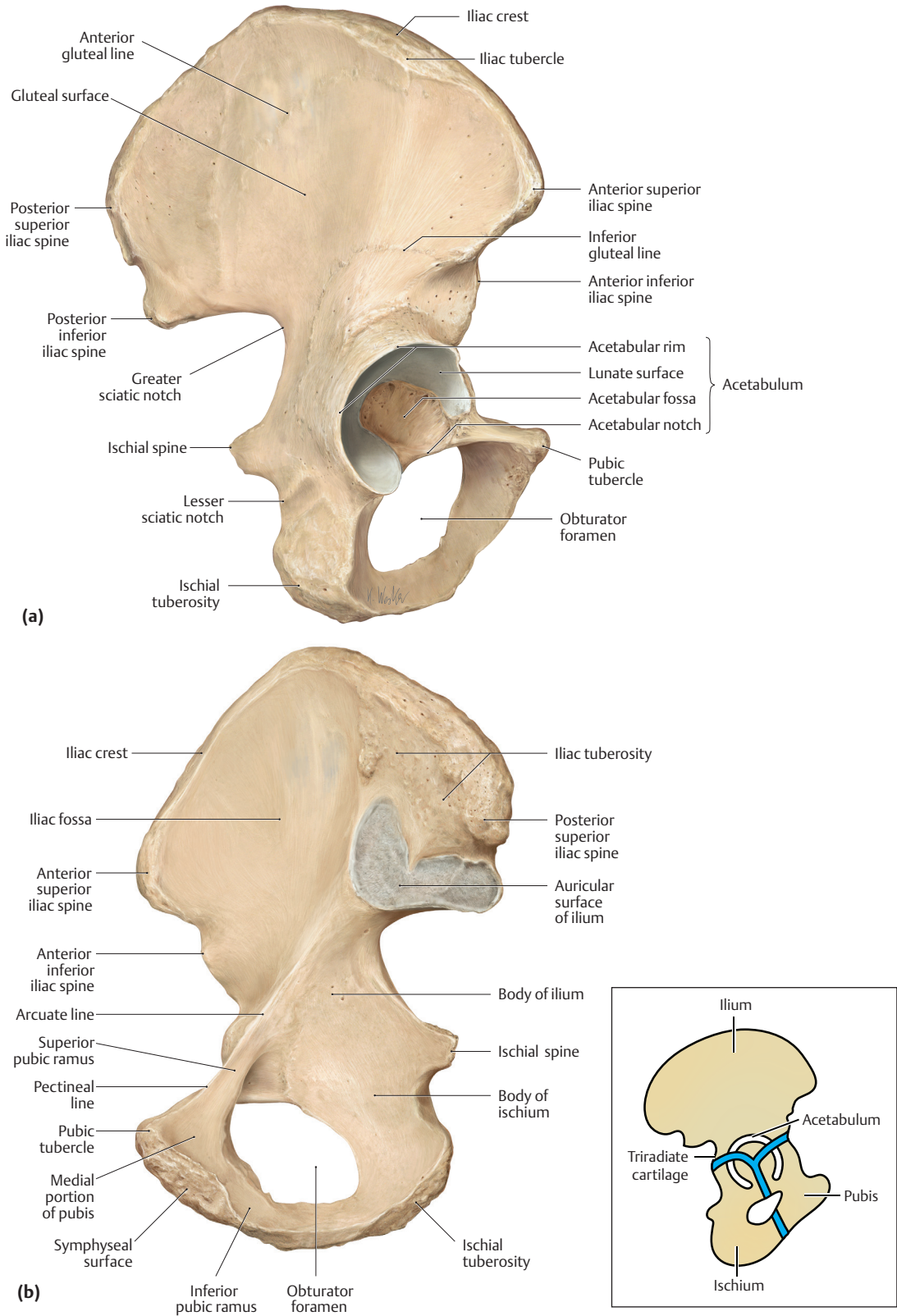


Fig. 1.3 Right hip bone. **(a)** Lateral view. **(b)** Medial view. (Reproduced with permission from Schuenke M, Schulte E, Schumacher U. Thieme Atlas of Anatomy. General Anatomy and Musculoskeletal System. Illustrations by Voll M. and Wesker K. © Thieme 2020). The figure in the inset shows three primary components of the hip bone.

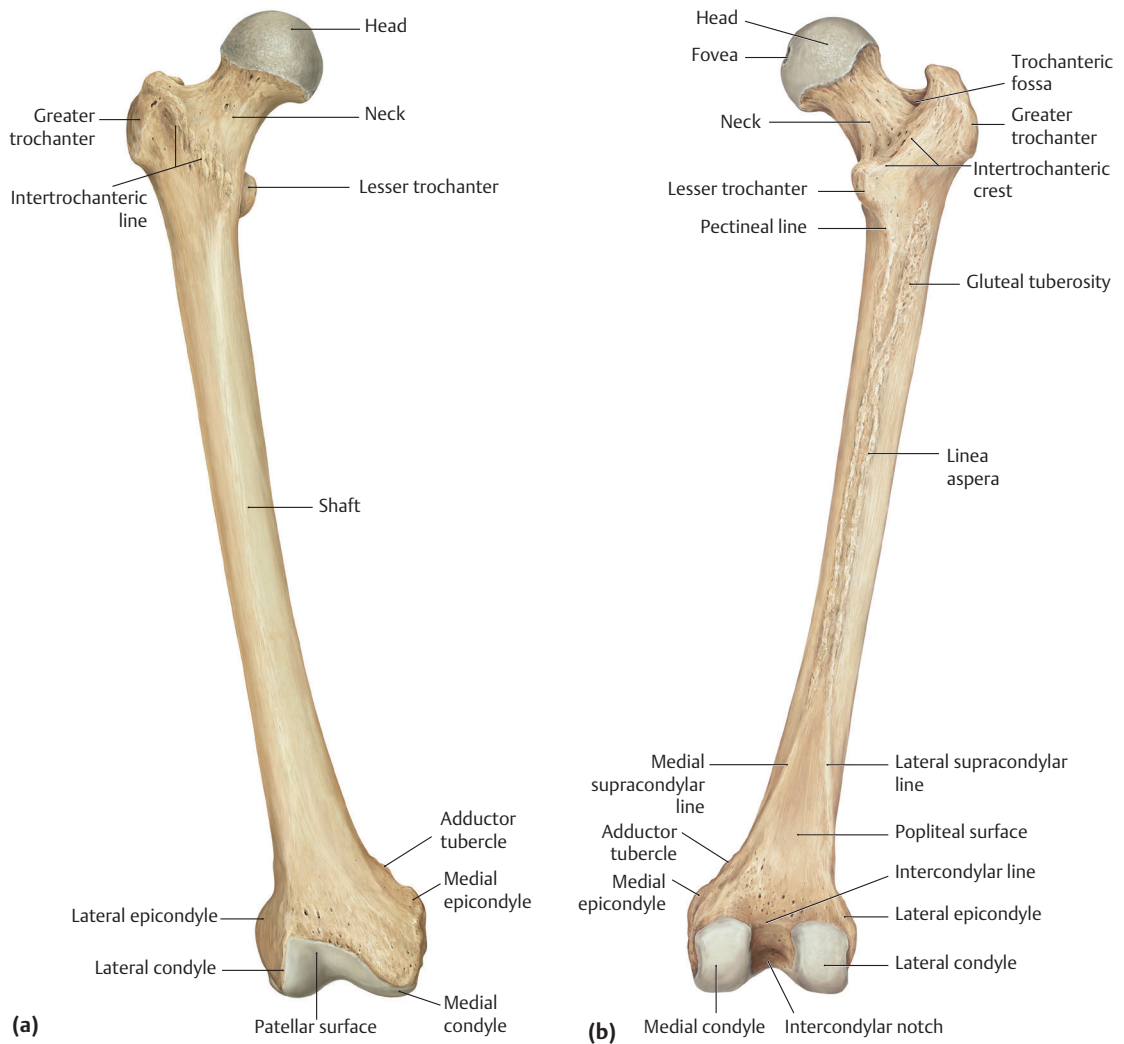


Fig. 1.4 Right femur. **(a)** Anterior view. **(b)** Posterior view. (Reproduced with permission from Schuenke M, Schulte E, Schumacher U. Thieme Atlas of Anatomy. General Anatomy and Musculoskeletal System. Illustrations by Voll M. and Wesker K. © Thieme 2020.)

3. Femoral shaft: It constitutes the length of the bone. At its upper end, it carries the greater trochanter placed superolaterally and the lesser trochanter placed posteromedially. Anteriorly the rough intertrochanteric line and posteriorly the smooth trochanteric crest demarcate the junction between the shaft and the neck. The linea aspera is the crest seen running longitudinally along the posterior surface of the femur. It splits in the lower portion into the medial and lateral supracondylar lines. The medial supracondylar line terminates at the adductor tubercle.

The lower end of the femur presents the medial and lateral condyles. These condyles bear the articular surfaces for articulation with the tibia at the knee joint. The two condyles are in the same horizontal plane when the femur is in its anatomical position. The lateral condyle is more prominent than the medial condyle, which prevents the lateral displacement of the patella. The condyles are separated posteriorly and inferiorly by a deep *intercondylar notch/fossa*. Anteriorly, the lower femoral aspect presents a saddle-shaped smooth surface for articulation with the posterior surface of the patella to form the patellofemoral joint.

Tibia (shin bone; **Fig. 1.5**): The tibia is the medial bone of the leg. It is the second largest bone of the body and transfers the body weight from the femur to the talus. It presents the following characteristic features:

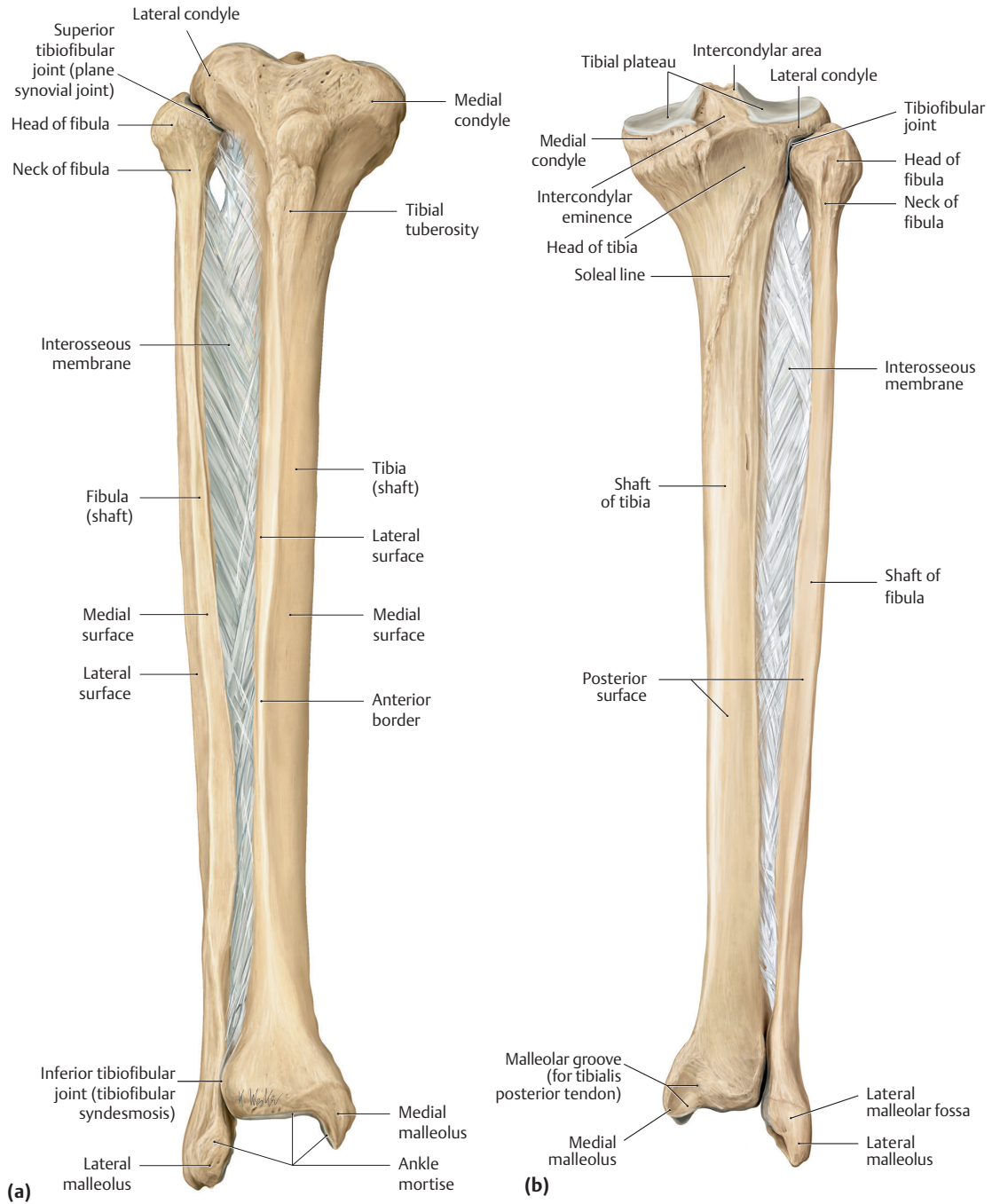


Fig. 1.5 Tibia and fibula (right side). **(a)** Anterior view. **(b)** Posterior view. (Reproduced with permission from Schuenke M, Schulte E, Schumacher U. Thieme Atlas of Anatomy. General Anatomy and Musculoskeletal System. Illustrations by Voll M. and Wesker K. © Thieme 2020.)

1. The proximal end of the tibia widens to form the medial and lateral condyles. The flattened upper end of the *tibia–tibial plateau*—comprises two smooth articular cartilages over the medial and lateral tibial condyles for articulation with the respective femoral condyles. In contrast to the femur, the medial tibial condyle is larger of the two.
2. The intercondylar area is the space between the two articular surfaces on the tibial condyles. It presents two projections, the *medial* and *lateral intercondylar tubercles*. Together, these tubercles constitute the *intercondylar eminence*.

3. The shaft of the tibia is triangular in cross-section. It has anterior, medial, and lateral borders and posterior, lateral, and medial surfaces.
4. The anterior border of the tibia is the most prominent border. At its upper end, there is a *tibial tuberosity*, which is easily identifiable. It provides attachment to the ligamentum patellae.
5. The anterior border and medial surface of the shaft are subcutaneous throughout its length and are often termed the *shin*.
6. On the posterior surface of the proximal part of the tibial shaft, there is an oblique line, the soleal line, which provides the tibial origin of the soleus. The popliteus muscle is often inserted into the triangular area above the soleal line.
7. The fibula articulates with the tibia superiorly at an articular facet on the posteroinferior aspect of the lateral condyle to form the *superior tibiofibular joint*.
8. The fibular notch situated laterally on the lower end of the tibia articulates with the fibula to form the *inferior tibiofibular joint*.
9. The tibia projects inferiorly as the *medial malleolus*, which constitutes the medial part of the mortise that stabilizes the talus. The medial malleolus is grooved posteriorly for the passage of the tendon of the tibialis posterior muscle.

Fibula (Fig. 1.5): The fibula is the lateral bone of the leg. It is not a part of the knee joint and has no function in weight transmission. The main functions of the fibula are to provide attachment to the muscles and also to participate in the formation of the ankle joint. It presents the following characteristic features:

1. Its upper end is called the *head of the fibula*, which presents the styloid process, a prominence on to which the tendon of the biceps femoris is inserted.
2. A constriction below the head is called the *fibular neck*. It separates the head from the fibular shaft. The common peroneal nerve is in close relation, as it winds around the lateral aspect of the neck before it divides into the superficial and deep peroneal nerves.
3. The fibula is triangular in cross-section. It has anterior, medial (interosseous), and posterior borders with anterior, lateral, and posterior surfaces. A vertical ridge, the medial crest, is on the posterior surface, which divides into the medial and lateral parts.
4. The lower end of the fibula enlarges and is prolonged inferiorly to form the *lateral malleolus*. It is the lateral part of the mortise that stabilizes the talus. It bears a smooth triangular articular facet on the medial surface for articulation with the talus. The area above the articular facet is rough to provide attachment to the tibiofibular ligament. The posterior aspect of the malleolus bears a groove for the passage of the tendons of the peroneus longus and brevis muscles. The lateral malleolus projects more downward than the medial malleolus.

Patella (kneecap; Fig. 1.6): It is a flat triangular bone located in front of the knee joint.

1. The patella is the largest sesamoid bone in the tendon of the quadriceps femoris.
2. The ligamentum patellae, which extends between the apex of the patella and the tibial tuberosity, is the true insertion of the quadriceps femoris.
3. The posterior surface of the patella bears a smooth articular surface, which is covered with articular cartilage. It is divided into a large lateral facet and a smaller medial facet for articulation with the femoral condyles.
4. The anterior surface of the patella is subcutaneous.

Bones of the foot (Fig. 1.7): The foot bones comprise the following:

1. Tarsal bones.
2. Metatarsals.
3. Phalanges.

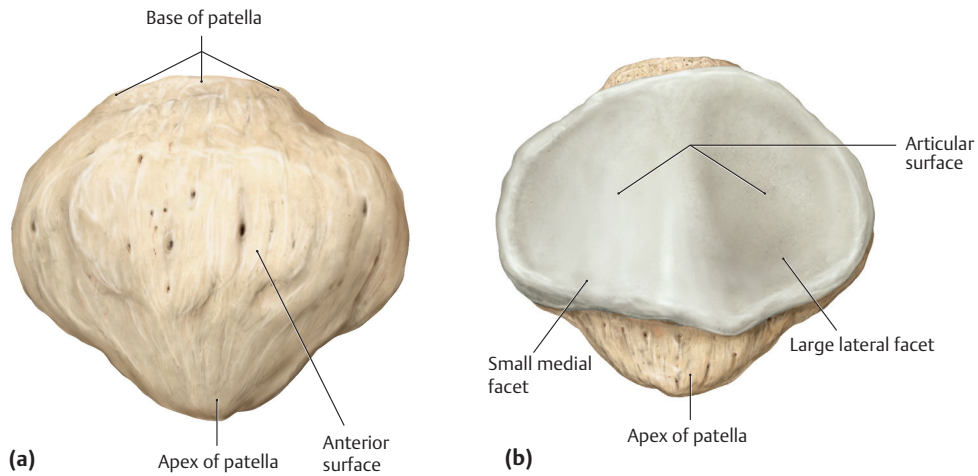


Fig. 1.6 Patella (right side). **(a)** Anterior view. **(b)** Posterior view. (Reproduced with permission from Schuenke M, Schulte E, Schumacher U. Thieme Atlas of Anatomy. General Anatomy and Musculoskeletal System. Illustrations by Voll M. and Wesker K. © Thieme 2020.)

Tarsal bones: The tarsal bones are arranged in two rows. The proximal row consists of two large bones (calcaneus and talus) set one above the other.

Calcaneus (Figs. 1.7a, b and 1.8b): The calcaneus is the largest tarsal bone forming the skeleton of the foot. Its superior surface articulates with the talus to form the *subtalar joint*. The inferior surface presents the medial and lateral tubercles at the proximal end. The medial surface presents a distinctive shelflike projection called the *sustentaculum tali*. The lateral surface presents a *peroneal tubercle*. The anterior surface presents a facet for articulation with the cuboid. The posterior surface presents a roughened middle part for attachment to the tendo calcaneus.

Talus (Figs. 1.7a, b and 1.8a): The talus forms a connecting link between the bones of the foot and leg. It presents the head, neck, and body. The body presents facets on its superior, medial, and lateral surfaces for articulation with the tibia, medial malleolus, and lateral malleolus, respectively. There is a groove on the posterior surface for the tendon of the flexor hallucis longus. The head projects distally and articulates with the navicular bone. The neck connecting the body and head presents a groove called the sinus tarsi.

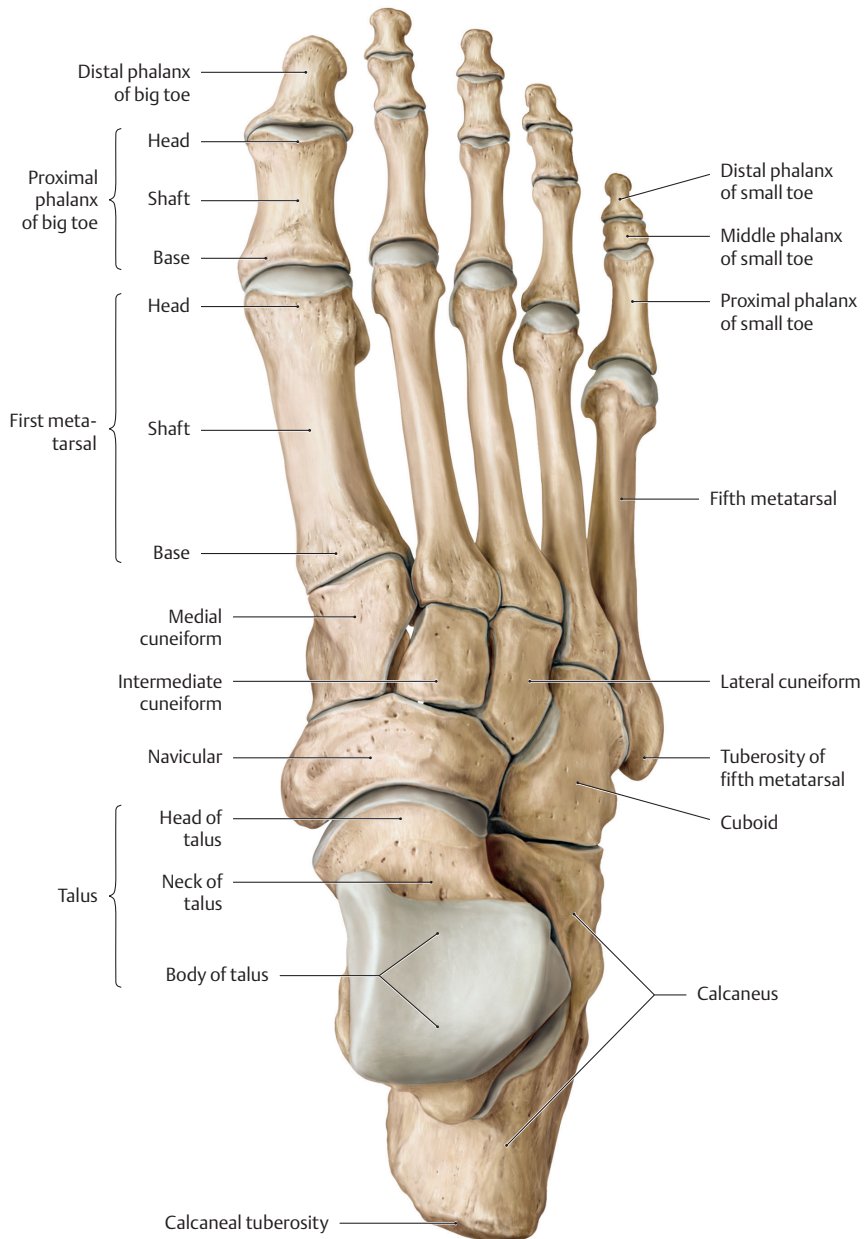
Cuboid (Fig. 1.7a, b): As the name implies, it is cuboid in shape. It articulates proximally with the calcaneus and distally with the fourth and fifth metatarsals. Its undersurface is grooved for the tendon of the peroneus longus.

Navicular (Fig. 1.7a, b): Navicular is boat-shaped. It articulates proximally by the concave facet with the head of the talus and distally with the three cuneiforms. It presents a tuberosity on its medial aspect for attachment to the tibialis posterior.

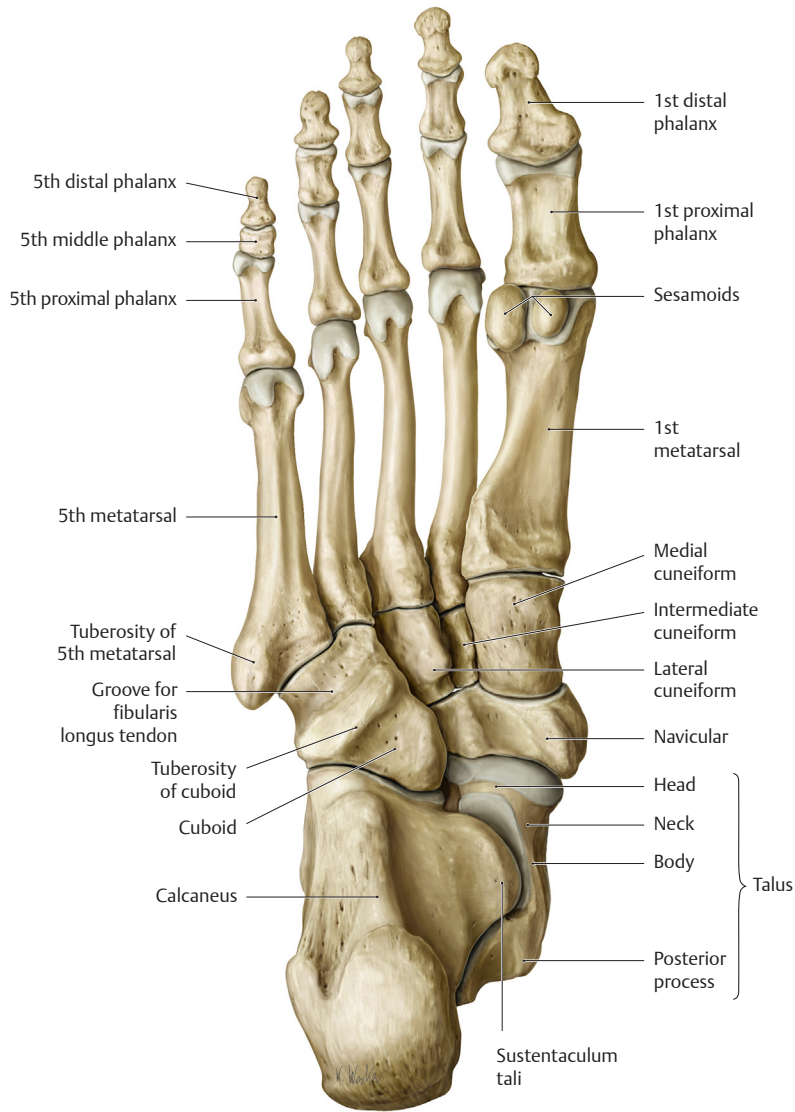
Cuneiforms (Fig. 1.7a, b): There are three cuneiforms: medial, intermediate, and lateral. They articulate anteriorly with the first, second, and third metatarsals, respectively.

Metatarsals (Fig. 1.7a, b): The metatarsals are five miniature long bones and are numbered 1 to 5 from the medial side. Their proximal ends articulate with the tarsal bones. The distal end (bead) of each metatarsal articulates with the base of the proximal phalanx of the corresponding toe. The first metatarsal is the largest and the inferior surface of its head is grooved for two sesamoid bones.

Phalanges (Fig. 1.7a, b): The phalanges are miniature long bones of the toes. In each toe, there are three phalanges (proximal, middle, and distal), except in the great toe, which has only two phalanges (proximal and distal). The proximal end of each phalanx is its base and the distal end is its head. The phalanges articulate with each other at the interphalangeal joints.



(a) Bones of the right foot (dorsal view). (Continued)



(b)

Fig. 1.7 (Continued) **(b)** Bones of the right foot (ventral view). (Reproduced with permission from Schuenke M, Schulte E, Schumacher U. Thieme Atlas of Anatomy. General Anatomy and Musculoskeletal System. Illustrations by Voll M. and Wesker K. © Thieme 2020.)

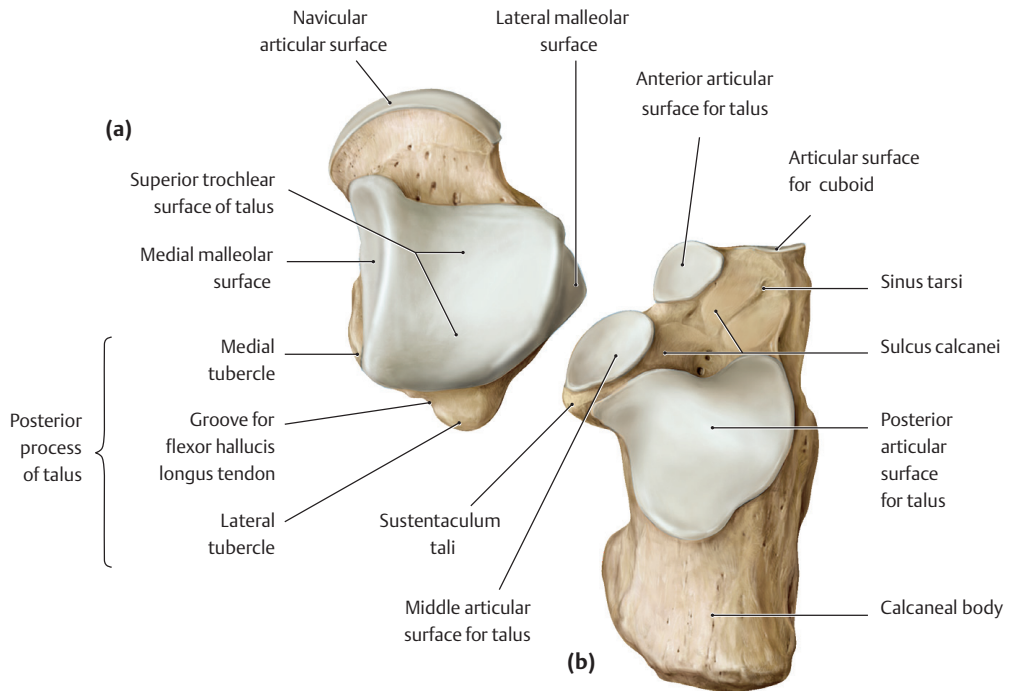


Fig. 1.8 (a) Right talus (dorsal view) and (b) right calcaneus (dorsal view). (Reproduced with permission from Schuenke M, Schulte E, Schumacher U. Thieme Atlas of Anatomy. General Anatomy and Musculoskeletal System. Illustrations by Voll M. and Wesker K. © Thieme 2020.)

